



## UTILIZATION OF DONOR CORNEAL RIM CULTURE IN CORNEAL TRANSPLANT PATIENTS IN TERTIARY CARE CENTRE, WESTERN INDIA

MODI K.P.\*, VEGAD M.M., SONI S.T., MURAWALA S.M., TRIVEDI M., AGGARWAL N.

Department of Microbiology, B.J. Medical College, Ahmedabad-380016, Gujarat, India.

\*Corresponding Author Email: [kairvi29490@gmail.com](mailto:kairvi29490@gmail.com)

Received: September 23, 2015; Revised: October 01, 2015; Accepted: October 04, 2015

**Abstract- Background-** The most serious complication occurring after keratoplasty is post-operative ocular infection due to contamination of the donor corneal button before transplantation leading to loss of vision and transplantation failure. The present study was undertaken to evaluate the utility of the donor corneal rim culture and their relationship with post-operative endophthalmitis.

**Materials and Methods-** We analysed 50 consecutive penetrating keratoplasties (PK) to determine the frequency of positive donor rim cultures. Donated eyes were collected by using aseptic precautions and after transplanting the cornea, corneal rim of donor was cultured for the isolation of bacteria.

**Results-** In the present study, 28% corneal rim cultures yielded microorganisms, mostly gram-negative bacilli. We isolated *Acinetobacter* spp. 14%, *Pseudomonas aeruginosa* 8%, *Enterococcus faecium* 2%, *Providencia* spp. 2%, *Candida* spp. 2% in donor rim culture.

**Conclusion-** We concluded that it is essential to perform donor corneal rim cultures in patients undergoing corneal transplantation to prevent complications like post-transplant endophthalmitis and corneal ulcer which leads to graft failure. In culture positive isolates we can change from empirical treatment to specific drugs as per antibiotic susceptibility report of donor rim culture.

**Keywords:** Keratoplasty, Donor cornea, Corneal rim, Endophthalmitis.

**Citation:** Modi K.P., et al., (2015) Utilization of Donor Corneal Rim Culture in Corneal Transplant Patients in Tertiary Care Centre, Western India. International Journal of Microbiology Research, ISSN: 0975-5276 & E-ISSN: 0975-9174, Volume 7, Issue 5, pp.-676-678.

**Copyright:** Copyright©2015 Modi K.P., et. al., This is an open-access article distributed under the terms of the Creative Commons Attribution License, which permits unrestricted use, distribution and reproduction in any medium, provided the original author and source are credited.

### Introduction

The cornea is a transparent, a vascular, watch glass like structure forming anterior one-sixth of the outer fibrous coat of the eyeball [1]. Cornea may be affected by various insults via infections, inflammations, trauma, allergy, hereditary, nutritional and metabolic disorders because of anatomical position in eye-ball. WHO defines blindness as inability to count fingers in daylight at a distance of 3 metres to indicate vision less than 3/60 (Snellen) or its equivalent. As per latest survey considering WHO definition of blindness, it is estimated that there are currently 285 million people are estimated to be visually impaired; 39 million blind and 246 million have with low vision of which 5.1% of people are due to corneal diseases. Approximately 75% of these eyes need keratoplasty [2]. Keratoplasty, define as corneal grafting or corneal transplantation, is an operation in which the patient's diseased cornea is replaced by the donor's healthy cornea. The technique of corneal grafting was first performed in 1817 by Reisinger in chickens and rabbits. In 1906, Zirm did the first successful penetrating corneal graft in humans. Corneal transplantation is now become a frequently performed procedure which has been made successful by advances in eye banking, corneal surgery and postoperative treatment. The most serious complication occurring after keratoplasty is post-operative ocular infection due to contamination of the donor corneal button before transplantation leading to loss of eye.

Thus, the present study was undertaken to assess the use of the donor corneal rim culture to prevent endophthalmitis and ulcer in post penetrating keratoplasty patients.

### Material and Methods

This study was conducted during time periods of December 2014 to May 2015 at tertiary care centre, western India. 50 corneal rim cultures were done in, the Department of Microbiology. All the calls for eye donation were attended and eyes were collected by using all aseptic technique by ophthalmology department. The information about donors had been collected as follows:

- Name of donor
- Age / Sex
- Time since death
- Cause of death
- Whether the donor had undergone any eye surgery.

The donor's blood was collected to do tests for the *Hepatitis B* virus (HBV), the *Hepatitis C* virus (HCV), *Treponema pallidum* and the Human Immunodeficiency virus (HIV). The eye balls were transported to the eye bank in cold chain and donated eyes were examined by slit lamp bio microscopy for evaluation of the status of the cornea, the anterior segment evaluation and evaluation of the lens status and by specular microscopy for the endothelial cell count. By slit lamp biomicroscopy, the corneas were examined by ophthalmologist for any epithelial defects, stromal cloudiness, arcus senilis and folds in the descemet's membrane. On the basis of these examinations, the corneas were graded by ophthalmologist as excellent, very good, good, fair and unacceptable for transplantation [3]. All unacceptable corneas were discarded. All this procedures were done by Department of ophthalmology. Under all aseptic precautions, the corneal buttons

were prepared and stored in McCarey's and Kaufman's (MK) medium [Fig-1]. At the time of surgery (Penetrating Keratoplasty), the donor cornea was trephined and the corneoscleral rim was placed in a dry, sterile container and wash out with a continuous flow of sterile normal saline [4]. This donor rim is transported to Microbiology department for donor rim culture by sterile aseptic precautions in McCarey's and Kaufman's (MK) media. The donor corneal rim were cultured in "C" OR "S" shape on Blood agar, Chocolate agar and MacConkey's agar for the isolation of microorganisms [5]. The growth on the culture media was identified by standard biochemical methods. The antibiotic susceptibility of isolated microorganisms on Mueller Hinton agar plates were evaluated by Modified Kirby-Bauer disk diffusion method as per the Clinical Laboratory Standard institute[CLSI] guidelines. In our study, we isolated carbapenem resistant strains of Gram-negative bacilli. Further detection of resistant isolates were done by Metallo betalactamase test [6].

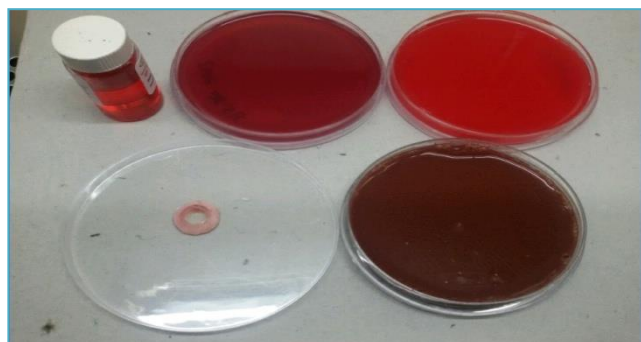
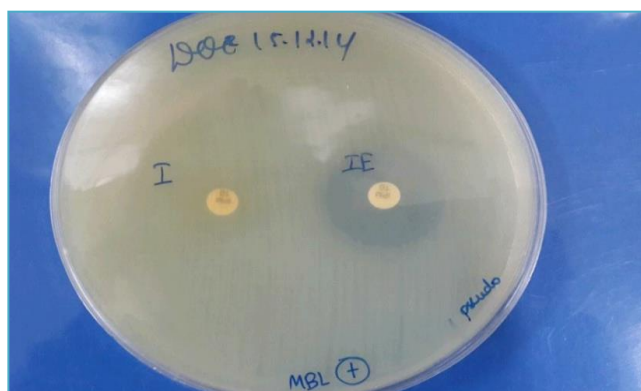


Fig-1 McCarey's and Kaufman's (MK) medium and Agar plates

**Detection of class B carbapenemase by combined disc synergy test (CDST):** We use phenotypic method CDST by streaking a lawn of the test strain on Muller Hinton agar for detection of carbapenemase [Fig-2]. Use of two discs, one with carbapenem antibiotic (imipenem 10mcg) and, the other with an inhibitor (imipenem with EDTA). An increase in the Zone diameter around the disc with inhibitor by 4-5 mm or above over the carbapenem disc indicate positive Metallobetalactamase production [6].

Fig 2- Detection of class B carbapenemase by combined disc synergy test (CDST)



### Observations and Results

Out of 50 donor rim cultures, 36(72%) corneo-scleral rims were sterile. Cultures of the donor rims were revealed the presence of microorganisms in 14(28%) eyeballs. Gram-negative bacilli were noted in 12(24%) donor rim cultures, gram positive in 1(2%), and fungus was noted in 1 (2%) donor rim culture [Table-1]. Antibiotics were given to the corneal transplant patients as per the antibiotic susceptibility testing report of the donor rim culture. Among 12 isolated gram negative bacilli, carbapenem resistant strains was detected in 5 isolates. Out of these 4 were *Acinetobacter* spp. and 1 was *Pseudomonas aeruginosa*. Endophthalmitis not develop in every rim culture positive cases. In our study endophthalmitis was developed in one of the post-penetrating

keratoplasty (PK) patient with, where the donor corneoscleral rim culture was positive for *Pseudomonas aeruginosa*. This *Pseudomonas aeruginosa* strain was sensitive to Imipenem, Amikacin, Gentamicin and Tobramycin, ciprofloxacin and levofloxacin. But it was resistant to Ceftazidime and Piperacillin. The patient was treated topical eye drops of Ciprofloxacin and Amikacin along with intravenous Ciprofloxacin and corticosteroids and intravitreal Amikacin and dexamethasone. The patient was recovered after 5 days of treatment.

Table-1 Organisms isolated from Corneal rim cultures

ORGANISMS	NUMBER AND PERCENTAGE OF EYE BALLS INFECTED
<i>Acinetobacter</i> spp.	7(14%)
<i>Pseudomonas aeruginosa</i>	4(8%)
<i>Enterococcus faecium</i>	1(2%)
<i>Candida</i> spp.	1(2%)
<i>Providencia</i> spp.	1(2%)
Total	14(28%)

### Discussion

#### Causes of failure of corneal transplants.

A failed corneal transplant generally looks cloudy and dull, making the vision very blurred. Following are commonest reasons for corneal transplant failure.

- **Rejection** may lead to failure of the transplant, which may happen immediately or sometimes may happen sometime later. [7]
- **Failure of the endothelium** (or decompensation) means that the graft no longer has enough cells on its inner surface to keep it clear, and so it must be replaced.[7]
- **Recurrence of the original disease** can happen to people whose corneal graft was done because of a genetic disease (corneal dystrophy) or an infection (viral keratitis). [ 7]
- **Unacceptable refractive result** means that the graft cannot be made to focus satisfactorily for its recipient, perhaps because of marked astigmatism. Such a graft may have to be considered as a failure, and replaced. [7]
- **Infection** causing ulceration or endophthalmitis leading to scarring, may occasionally cause graft failure.[7]

Endophthalmitis is a rare but catastrophic complication of any penetrating keratoplasty (PK). Several factors put patients who undergo penetrating keratoplasty at an increased theoretical risk for endophthalmitis by large wounds with prolonged exposure to conjunctival flora and with donor tissue that harbouring pathogens [3,4].

Endophthalmitis following corneal transplantation may also be associated

- with the vitreous wick or
- it may be followed by the ulcerative process in the graft or
- suture abscess formation or
- due to the bacterial access to the anterior chamber which is associated with the loose sutures. [8].

Wilhelmus *et al.*, reported 14% positive donor rim cultures, 0.2% of which developed endophthalmitis. In our study we find that out of 50 eyes 28% positive donor rim cultures and endophthalmitis develop in 7.5% of the positive donor rim cultures [9]. Kloess *et al* reported the isolation of *Candida albicans* from donor rim cultures. In our study we reported *Candida* spp. In 2% among 50 donor rim cultures [10]. Lohiya S *et al* reported 13.4% corneoscleral rim culture positivity and the organism, which was commonly isolated, was coagulase negative staphylococcus (CONS). But In our study, we reported gram negative bacilli *Acinetobacter* spp.(14%) as common isolate among 50 donor rim culture [11].

### Conclusion

We concluded that it is essential to perform donor corneoscleral rim cultures in

patients undergoing corneal transplantation to prevent complications like post-operative endophthalmitis and corneal ulcer which leads to graft rejection. In culture positive isolates we can change from empirical treatment to specific drugs as per antibiotic susceptibility report of donor rim culture.

## References

- [1] Khurana A.K. (2009) 4<sup>th</sup> edition Diseases of cornea chapter no. 5<sup>th</sup> pg-89.
- [2] Global data on visual impairments (2010) *World Health Organization*, pg no:3
- [3] Tissue bank international post-mortem corneal excision and tissue evaluation, in Appendix 2. (2000) *Corneal Disorders – Clinical Diagnosis & Management* 2<sup>nd</sup> Ed. In Leibowitz, Waring;:P 893-909.
- [4] Collee J.G., Miles R.S., Watt B. (2012) *Test for identification of bacterias*, in chapter 7. *Mackie & McCartney's Practical Medical Microbiology* 14<sup>th</sup> Ed. In : JG Collee. AG Fraser, BP Marmion, A Simmons, Editors.
- [5] Jagsish Chandra (2008) *Text book of mycology* 3<sup>rd</sup> edition ch: 27 *oculomycosis* pg: 404 Churchill Livingston: Indian. Reprint; P 131-49.
- [6] Clinical and Laboratory Standards Institute (2015) *Performance standard for antimicrobial susceptibility test for Bacteria that grow aerobically approved standard; approved standards, 10th Edition. CLSI document Mo 7-A10.*
- [7] Stephen J. Morgan (2001) *FRCO phth., D.O., Consultant Ophthalmologist, City Hospitals Sunderland and North Durham Acute Hospitals NHS Trusts:*  
[http://www.moorfieldsresearch.org.uk/orntemp/PatientInfo/Areas/Cr\\_Graft.htm](http://www.moorfieldsresearch.org.uk/orntemp/PatientInfo/Areas/Cr_Graft.htm)
- [8] Meredith T.A. (2006) *Vitreotomy for infectious Endophthalmitis. 4<sup>th</sup> Edition* S.G. Ryan. *Retina volume 3. Edited by C.P .Wilkinson* Elsevier Mosby; 2254-75.
- [9] Wilhelmus K.R, Hassan S.S. (2007) *Ophthalmology*, 114(3):440-5.
- [10] Kloess et al. (1993) *American journal of ophthalmology*, 115: 309- 316.
- [11] Lohiya S., Singh S., Attal R., Basak S. (2011) *Journal of Clinical and Diagnostic Research*, 5(3), 589-591.